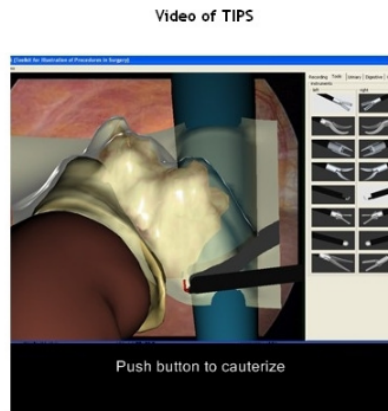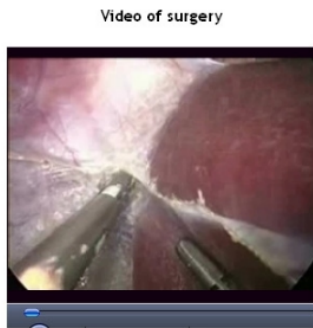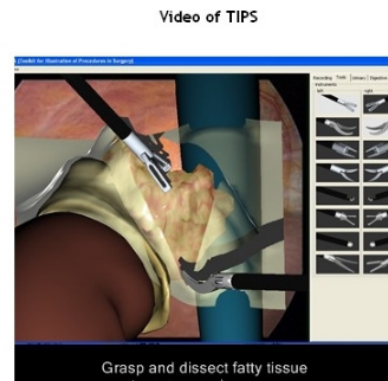
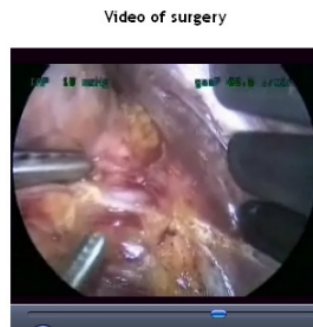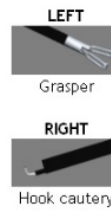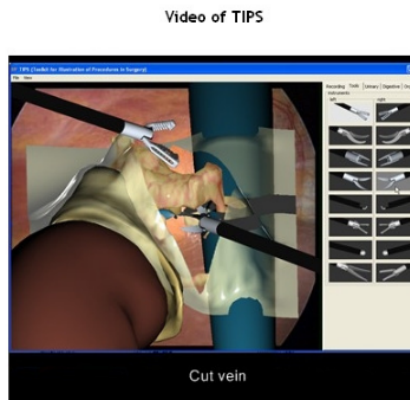


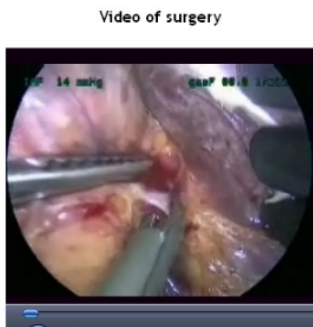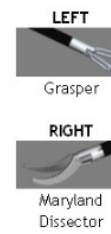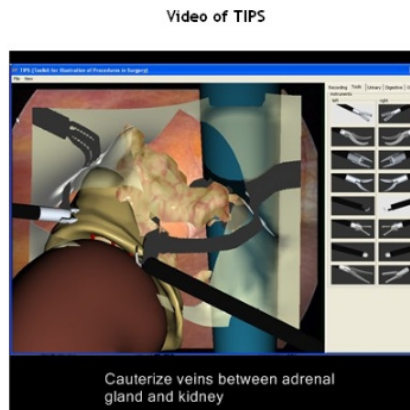
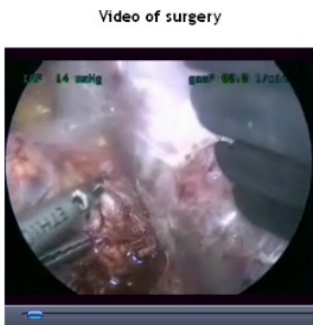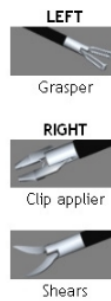
Tools Used



Tools Used



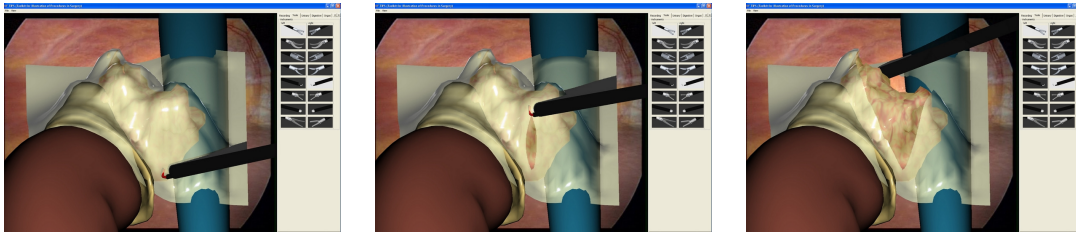
Tools Used



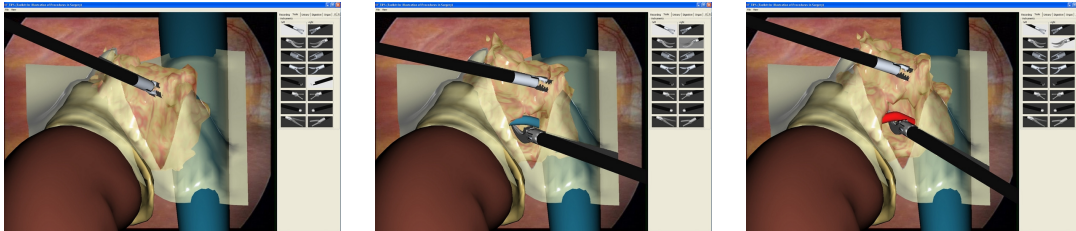
Tools Used



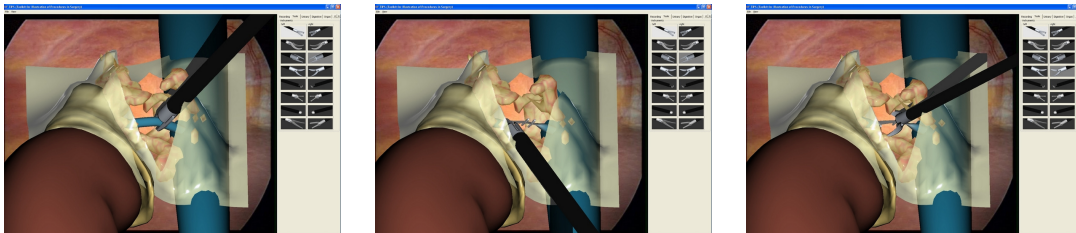
Figure Appendix-1: Adrenalectomy steps



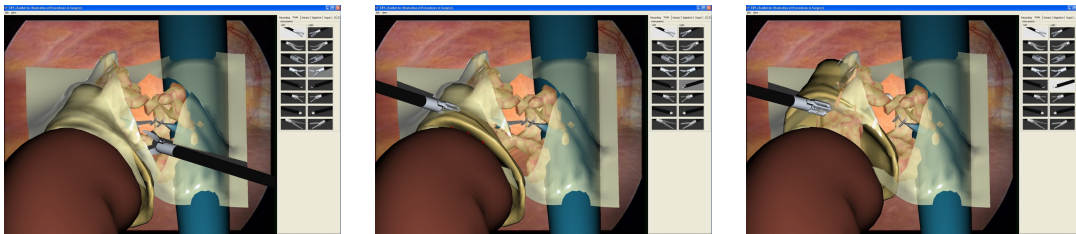
(a) incising the peritoneum



(b) exposing the adrenal vein (beware of rupture!)



(c) clamping the adrenal vein



(d) removal of the adrenal gland

Figure Appendix-2: Adrenalectomy computer-simulated case.